

## Appropriate early orthodontic treatment - 2

The last issue of 'Mouthing off' discussed appropriate early orthodontic treatment in general. In this and subsequent issues we expand on that subject with more specific information and illustrated examples.

### Protruded maxillary incisors

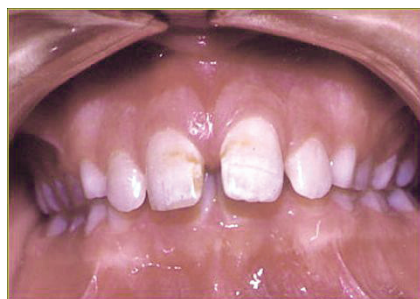
There are multiple causes of such protrusion, including the forward eruption of the upper incisors perpetuated by the lower lip sitting up under the upper incisors at rest – as illustrated here. Other causes are: Class II malocclusion, thumb sucking or other oral habit, lip incompetence or muscle function, large upper incisors and/or a large upper midline frenum.

The major reasons for treating such patients in the mixed dentition are to reduce risk of accidental damage to the upper incisors and to improve the child's appearance when that is affecting confidence or self esteem. Occasionally,

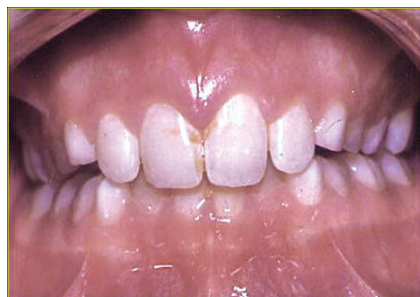
correction can also help the development of proper speech patterns, obtain proper oral seal, normalise the lip musculature and tongue position and minimise tongue thrust. It may also encourage balanced jaw growth, minimise the upper posterior teeth drifting forward and reduce upper incisor staining and gingivitis.

Early treatment may commonly involve the use of upper partial fixed appliances, a functional appliance or an upper removable plate.

Before treatment:



After 6 months:



### Impacted first permanent molars

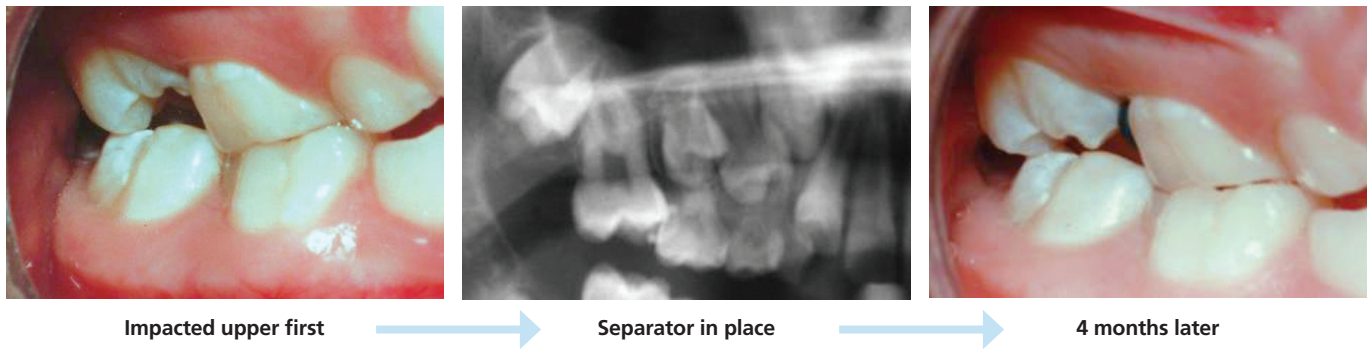
Occasionally, every dental practice sees an erupting first permanent molar impacted under the distal of the second deciduous molar.

If not corrected, the deciduous molar will be prematurely exfoliated and the first molar will rapidly drift mesially, totally blocking out the second premolar. This can lead to the patient

needing more extensive orthodontic treatment later and the probable loss of a premolar, sometimes by surgical removal.

When the impaction is mild, treatment might be as simple as placing an orthodontic separator between the two teeth.

This can be enough to free the physical contact. With the separator still in place, as shown in the photo on the right, the first permanent molar can continue to erupt down against the intact distal enamel of the second deciduous molar.

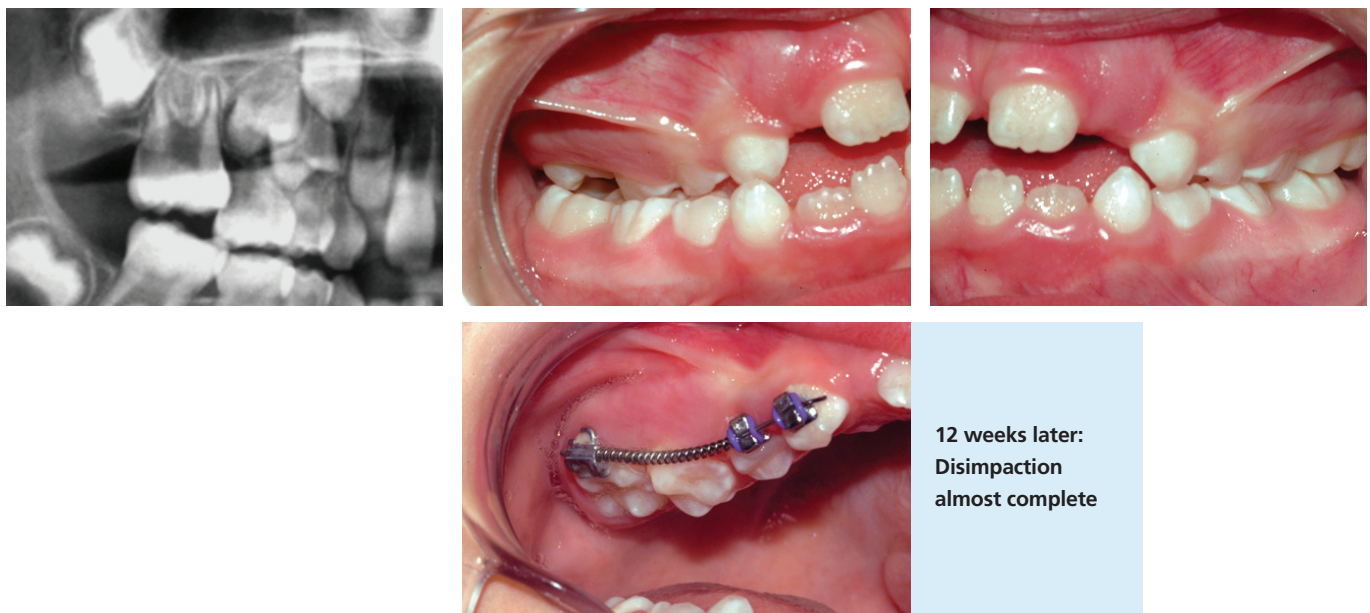


Impacted upper first

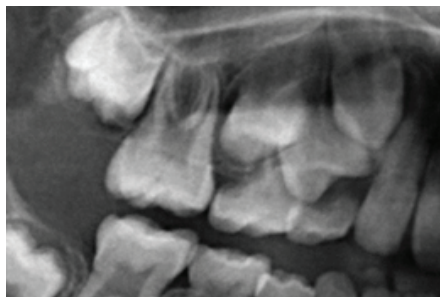Separator in place

4 months later

Often the impaction is more severe and a separator cannot be placed.



12 weeks later:  
Disimpaction  
almost complete



12 Months later:  
The second deciduous molar is still in place maintaining space for the second premolar

In such cases, the use of partial fixed appliances and a coil spring is one of the simpler techniques to distalise the first permanent molar. This is usually quick and rarely takes more than 12 to 16 weeks.

In the case illustrated here, the impaction has already resorbed the distal root of the second deciduous molar. With further resorption it is at risk of being prematurely exfoliated.

The photo taken 12 weeks later shows that the disimpaction is almost complete.

The xray image taken 12 months later shows that the second deciduous molar is still in place, maintaining space for the second premolar.

## Hills Orthodontics

### PENNANT HILLS

28 Fisher Avenue  
Telephone 02 9484 5154  
hillsorthodontics@yahoo.com.au  
www.orthoworld.com.au

Dr Daniel Vickers • Dr Ross Adams  
Dr Anita Bonic

