


Australian Society  
of Orthodontists



University of Sydney



# Moving Teeth *Invisibly* with Sequential Plastic Aligners

PART 1

*Creating Brighter Futures*

# Moving Teeth *Invisibly* with Sequential Plastic Aligners

## Introduction

Many potential orthodontic patients, and especially adults, are concerned about the appearance of their teeth but will not wear obvious orthodontic appliances and this has produced a demand for more aesthetic appliances. In 1999 Professor Milton Sims predicted that in time bracket systems would become redundant and teeth would be moved without having to wear obvious appliances (1). Active, sequential, plastic aligners are one of the more recent aesthetic appliances and a possible solution for many adults and some older teenagers. This article will discuss sequential aligner treatment, showing malocclusions and tooth movements which respond predictably and those which are more challenging, either unsuitable or requiring advanced skills to be treated successfully.

## History

The technique of minor tooth movement using removable, molded, appliances is not new. In 1945, Dr Harold Kesling (2) described how teeth may be sawn off a plaster cast and placed in corrected positions using soft wax like a diagnostic set up (Figure 1).

A rubber tooth positioning appliance was then fabricated over it, applying pressure to align the teeth. In 1994 Sheridan and colleagues (3) described the use of clear, vacuum-formed, thermoplastic appliances to correct minor rotations and malalignments.

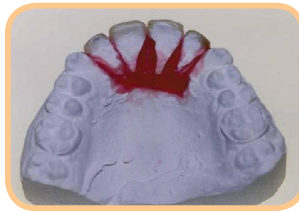

Figure 1 Teeth that are to be moved are cut off the model and reset using wax.

## Minor tooth movement

A technique similar to that described by Sheridan has been used for decades to correct minor rotations and close small anterior spaces. Figure 2 shows a patient with an unsightly space between the upper right central and lateral incisors. After eliminating periodontal disease as a cause, the maxillary incisors were repositioned in wax on the cast (Figure 1) and a semi transparent thermoplastic sheet was formed over the altered model. With full time wear the diastema was soon eliminated (Figure 2).

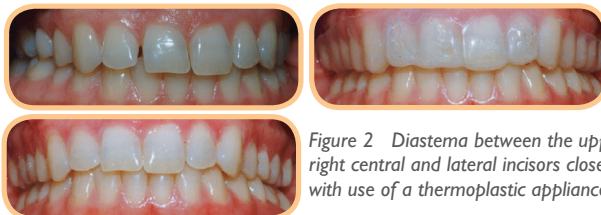

Figure 2 Diastema between the upper right central and lateral incisors closed with use of a thermoplastic appliance.

For more efficient alignment pressure can be exerted on teeth using pimples and divots placed in the thermoplastic appliance using divoting pliers (Figure 3). However, after a few repetitions

in the same position, the thermoplastic material becomes too stretched to be effective. Alternatively, additional tooth movement can be achieved by taking a new impression, repositioning the teeth further and pulling down a new thermoplastic appliance. Another alternative is to create a force against the tooth by temporarily bonding composite "bumps" onto the tooth surface and creating a space within the appliance on the opposite side of the tooth to accommodate movement.



Figure 3 Pliers used to create "dimples" in the plastic.

## Evolution of the technique

Since 1999 the technique of moving teeth using molded removable appliances has become a sophisticated commercially available laboratory service that seeks to treat more significant malocclusions. While repositioning teeth on plaster models is still appropriate for minor movements, and some companies still use this technique for more major movements (ClearSmile®), the use of powerful proprietary 3D software to reposition teeth virtually, has become 'the state of the art'. Invisalign™ is the most popular and well-known system using this technology. Polyvinyl siloxane impressions are couriered to the company where they are scanned. Records (Figure 4) can also be sent or submitted on line. Laboratory staff set up tooth movements according to the clinician's predetermined preferences and instructions and to the parameters set by the software. Using the proprietary viewer, the proposed movements are downloaded from the internet for review by the clinician. Treatment modifications can be made on-line until the treatment plan is accepted and manufacture of the

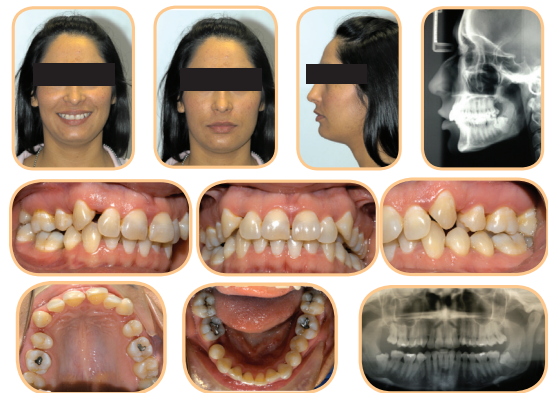

Figure 4 A full set of 8 photographs and an OPG are mandatory while a lateral cephalograph is also very useful in diagnosis

## Colgate CARE COLUMN

### Periodontitis as a risk factor for adverse pregnancy outcomes

Preterm Low Birth Weight (PLBW) and Preeclampsia (high blood pressure, protein in the urine, swelling, headaches and sudden weight gain during pregnancy) may produce long term health repercussions for the infants concerned. It appears periodontitis is a potential mediator in both these conditions.

Risk factors for PLBW Infants and Preeclampsia include maternal age, history of drug (prescribed and illicit) and alcohol intake, genetics, diabetes and history of acute inflammation – such as periodontitis. Biological mediators prostaglandin E2 (PGE2) and TNF are raised to artificially high levels by inflammation thus potentially inducing early labour. Lopez, 2002, showed providing periodontal therapy to women with periodontitis during pregnancy reduced the occurrence of PLBW.

The relationship between periodontal disease and Preeclampsia has not yet been proved, although a positive correlation has been shown. For both conditions further research is required, particularly what advice and treatment be given to expectant mothers and the benefits of this to the mother and child.

Lopez, NJ et al. Periodontal therapy may reduce the risk of preterm low birth weight in women with periodontal disease : a randomized controlled trial . J. Periodontology. 2002 Aug;73(8):911-924  
Further references available on request



sequential aligners begins. Each aligner can move teeth a maximum of 0.25mm; however difficult tooth movements are prescribed at a slower rate.

**Caution**

The computer software can be directed to produce an occlusion, alignment of teeth, rate of tooth movement and number of aligners that are unrealistic, more "cartoonodontics" than achievable. Therefore, orthodontic diagnosis, a knowledge of biomechanics, an understanding of the limitations of the appliance and readily available back-up skills such as fixed orthodontic appliances are very important when considering treatment using sequential plastic aligners, particularly in moderate to difficult cases.

The clinician must prescribe tooth movements and attachments required throughout the course of treatment before the first aligner is made. Flawed treatment planning and inadequate direction to the laboratory will inevitably result in unsatisfactory or unsuccessful treatment. Teeth can begin to intrude, will not fit accurately into the aligners and require mid-course corrections, producing disappointing overall results and unnecessarily extending treatment. The laboratory technician's skill is operating the computer software, not prescribing tooth movements. It is important to remember that the legal responsibility for the treatment remains with the clinician, not the laboratory.

Occasionally, during the course of treatment, patients can become increasingly demanding regarding treatment progress or the result. In order to avoid disappointment or aggravation, realistic expectations must be established during the consultation and treatment planning stages. Generally, clinicians will find it difficult to achieve the same precise results with sequential plastic aligners as they can with fixed appliances.

**Which malocclusions are easy and which are difficult?**

Class II and Class III cases often require fixed appliance adjuncts, possibly with extractions and therefore can automatically be considered advanced cases. Treatment of Class I cases is more predictable although, even within this group, some tooth movements are difficult to effect with aligners. It is therefore essential to analyse the types of tooth movement that will be required to correct the malocclusion in order to determine a realistic prognosis. In general, because plastic aligners push teeth, the greater the surface area in contact with the plastic, the better the tooth response. Teeth with long clinical crowns respond more favourably than those with short crowns.

**• Tipping teeth**

Plastic aligners, in common with all removable appliances, readily tip teeth. Figure 5 shows lower incisor alignment resolved by tipping teeth into a wider arch perimeter. However, excessive incisor tipping can compromise the profile and resting lip competence by eversion of the lower lip (Figure 6) and potentially cause gingival recession and dehiscences. As a rule of thumb, up to 6mm of lower arch crowding can be treated with aligners. With greater diagnostic knowledge and treatment experience it is possible to treat more severe crowding, possibly involving extraction. The case in Figure 7 with upright lower anterior teeth has a favourable prognosis for resolving the crowding because tipping the incisors labially will not result in excessive proclination.

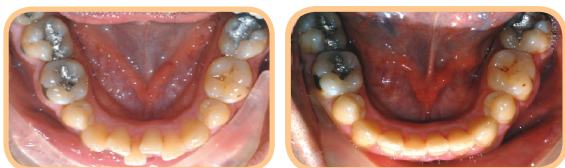

Figure 5 Lower anterior teeth have been aligned by arch expansion and incisor proclination

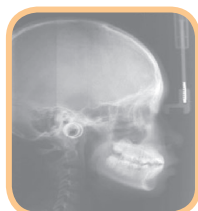

Figure 6 Excessively proclined incisors and associated eversion of the lower lip

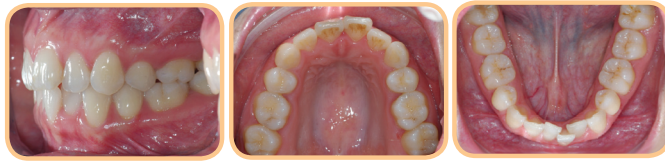

Figure 7 An example of a good introductory case for sequential plastic aligners: Class I crowding without excessive incisor proclination. (Courtesy of Dr A Wu)

**• Spacing**

Anterior space closure responds favourably to treatment using sequential plastic aligners provided there is adequate interproximal surface area contact with the aligner. The teeth are protected from functional and resting tongue pressures that are often responsible for the diastema. These forces usually persist after aligner treatment so permanent retention is often necessary (Figure 8).

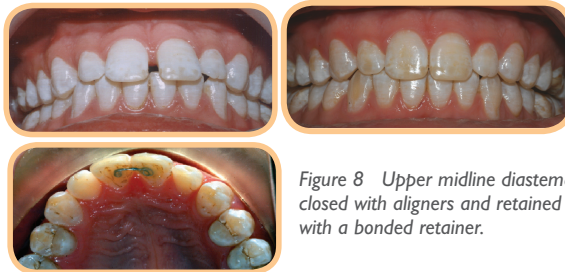

Figure 8 Upper midline diastema closed with aligners and retained with a bonded retainer.

The challenge in treating severe spacing problems is to keep the roots parallel and prevent the crowns tipping together during space closure. Initial movement of the roots proximally (mesial root tip) minimises mesial crown tip and produces more bodily movement. This is achieved by prescribing, in the 3D set up, the use of composite attachments to grip the teeth more positively to provide this root movement (Figure 9).

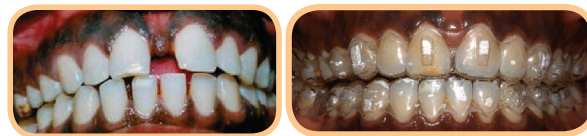


Figure 9 More significant spacing closed with aligners. Note composite attachments used to provide better leverage to move teeth and seat the aligners.

A technique that can be used to help close simple midline diastemas is to cut the thermoplastic aligner in half at the midline. Three sided tags are placed on the aligner for an elastic to close the space (Figure 10).

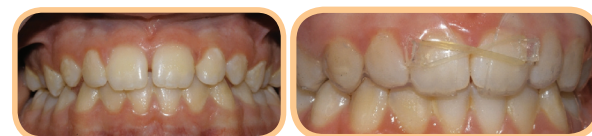

Figure 10 Midline diastema with aligner cut in the midline with elastic to close the diastema.

**• Expansion**

Dental expansion, but not orthopaedic expansion, is readily achieved with plastic aligners. As with fixed appliances, premolar expansion is more stable than canine expansion. In Figure 11 severely lingually tipped premolars were uprighted initially using sectional fixed appliances for four months followed by plastic aligner expansion. The brackets seen on the buccal of lower second molars are Class II elastic hooks.

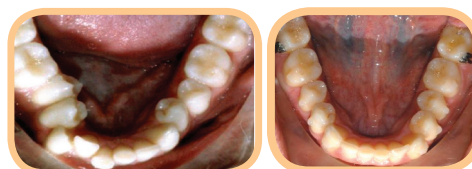

Figure 11 Expansion using segmental fixed appliances followed by plastic aligners. Note composite attachments or 'buttons' on premolars to help with retention of aligners.

Brighter Futures is published by the Australian Society of Orthodontists (NSW Branch) Inc. in conjunction with the Orthodontic Discipline at the University of Sydney.

The newsletter is intended to help keep the dental profession updated about contemporary orthodontics, and also to help foster co-operation within the dental team.

Without the generous support of Henry Schein Halas and Colgate, who are an integral part of the dental team, this publication would not be possible.

---

*The statements made and opinions expressed in this publication are those of the authors and are not official policy of, and do not imply endorsement by, the ASO (NSW Branch) Inc or the Sponsors.*

---

Correspondence is welcome and should be sent to:

Department of  
Orthodontics  
University of Sydney  
Sydney Dental Hospital  
2 Chalmers Street,  
Surry Hills NSW 2010

---

## AUTHOR & EDITORS

Dr Morris Rapaport  
PRINCIPAL AUTHOR

Prof M Ali Darendeliler  
Dr Dan Vickers  
Dr Michael Dineen  
Dr Ross Adams  
Ms Felicity Dougherty

[www.aso.org.au](http://www.aso.org.au)

### • Intrusion

Aligners can intrude anterior teeth 2 to 3mm quite efficiently to level a deep Curve of Spee for overbite reduction. The case in Figures 12 and 13 has a deep anterior overbite and severe wear of the lower anterior teeth. Overbite correction was achieved with upper and mainly lower incisor intrusion. Included is the Invisalign™ 3D representation of the mandibular arch.

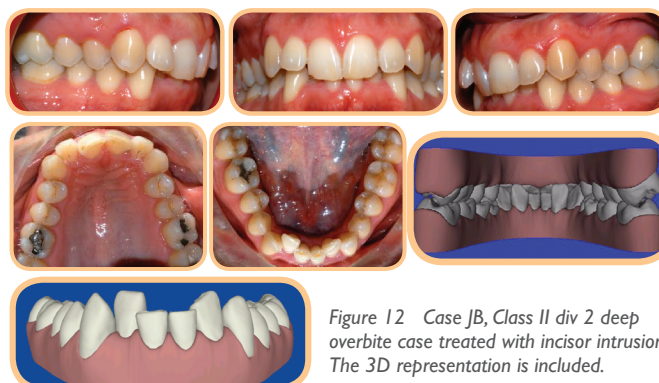


Figure 12 Case JB, Class II div 2 deep overbite case treated with incisor intrusion. The 3D representation is included.

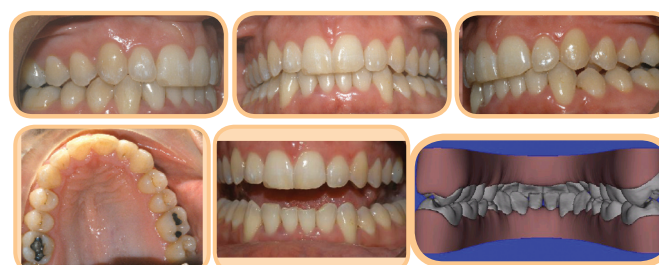

Figure 13 Case JB showing a significant amount of bite opening with the lower lateral incisors intruded almost down to the same level as the worn lower central incisors.

## Conclusion

'Sequential Plastic Aligner' treatment is an exciting development in the field of orthodontics both for patients and clinicians. However aligners are not as simple to use as it may seem at first glance. As with most dental treatment, success or failure depends very much on case selection and treatment planning before any aligners are made. Further discussion of the various tooth movements that this appliance can readily achieve, and also more difficult movements, will continue in the next issue of Brighter Futures (2009-2).

## References

1. Sims MR. Brackets, epitopes and flash memory cards: A futuristic view of clinical orthodontics. *Aust Orthod J* 1999;15:260-268
2. Kesling H The Philosophy of the Tooth Positioning Appliance *Am J Orthod* 1945; 31:297-304
3. Sheridan et al. Essix Appliances: Minor tooth movement with divots and windows. *J Clin Orthod*; 1994 Nov; 659-663

 HENRY SCHEIN® | HALAS  
Everything Dental.™

Your Dental One Stop Shop!